

The Use of an Antifungal Cream with Olivamine* in the Treatment of Cutaneous Candidiasis in Bariatric Patients

Becky L. Strilko, RN, APN, CWOCN¹ and Alison M. Barna, RN, MSN, CWON²


¹Silver Cross Hospital, Joliet, IL

²Provena Saint Joseph Medical Center, Joliet, IL

Study # LIT600

This study was sponsored by:

Educare[™]
wound & skin care education

The clinical education division of  MEDLINE

©2007 Medline Industries, Inc. One Medline Place, Mundelein, IL 60060
Medline and Educare are registered trademarks of Medline Industries, Inc.
1-800-MEDLINE (1-800-633-5463) www.medline.com

MKT207189/LIT600/2.5M/K&M7

The Use of an Antifungal Cream with Olivamine* in the Treatment of Cutaneous Candidiasis in Bariatric Patients

CLINICAL PROBLEM

Cutaneous Candidiasis is an infection of the skin caused by the fungus *Candida*. It may involve any skin surface on the body, but usually occurs in warm, moist creased areas, such as axilla, groin and skin folds. *Candida* infection is particularly common in our facility in individuals who are obese due to the multiple skin folds. Symptoms of a candida infection may include: itching, painful skin lesions/ulcerations, odor and rash. The rash may appear as erythema or inflammation with enlarged macules or papules. Satellite lesions are typically present. Diagnosis is primarily based on the appearance of the skin, particularly if risk factors are present.

OBJECTIVE

Evaluation of an antifungal cream containing Olivamine on bariatric patients with clinically diagnosed cutaneous *Candida* and improvement of their overall skin health. Olivamine is a proprietary blend of antioxidants, amino acids, vitamins and methylsulfonylmethane (MSM). These ingredients are all known to play a vital role in basic cellular construction and protection.

METHODOLOGY

Five morbidly obese patients were treated in the hospital setting for approximately one week. Criteria assessed included: fungal growth, pruritus, erythema/inflammation, skin ulcerations, pain and odor control.

CONCLUSION

Assessment of the patients after one week of treatment revealed a significant improvement in all areas of criteria. The Olivamine components made a difference in the patient's overall skin health by delivering vital nutrients to the skin.

BACKGROUND AND OBJECTIVE

Obese patient skin is characterized by the presence of folds, and a high level of sweat production (1). Infections involving *Candida albicans*, a species of fungus, are common in such patients, within skin folds as well as the groin and axilla. The infective pathogens colonize in warm moist areas. Such conditions can lead to the formation of pustules, which subsequently rupture leading to formation of new pustules in the periphery. There is further inflammation, pruritus, and significant discomfort to the patient. Diagnosis is usually performed via inspection and fungal culture (2). Secondary bacterial infections are common. Predisposing factors may be involved, such as hot weather, poor hygiene, tight clothing, skin disorders such as psoriasis, and the use of topical steroids (3).

Treatment has generally involved keeping the skin dry and clean using gentle cleansers, and using a local antifungal therapy such as an antifungal cream, powder or ointment (4). Oral antifungal medications are indicated if local interventions fail (5). The clinician should work with the patient to ensure that local treatments are used to maximize their benefit, so that oral drug regimens, with their associated side effects, may be avoided.

The purpose of this study was to evaluate an antifungal product that claims to provide nutrition as well as antioxidants to the damaged skin.

METHODS

In this prospective, non randomized, uncontrolled open label pilot study, five morbidly obese inpatients, clinically diagnosed with cutaneous candidiasis were recruited for the evaluation of an antifungal cream. The active ingredient: 2% miconazole nitrate is a well known antifungal agent. The product which also contains a complex blend of antioxidant (hydroxytyrosol), vitamins, amino acids, and methylsulfonylmethane, was applied to the affected skin of the patients on an as needed basis, and the patient skin was monitored daily for a week by the researchers. Criteria assessed included: degree of fungal growth, pruritus, erythema/inflammation, skin ulcerations, pain, and odor control. A numerical scale was used to assess each of the stated criteria, and the observations were recorded in the patient charts. Because of the study limitations (open label, non controlled, non randomized, limited sample size) no statistical evaluation was performed.

DISCUSSIONS

This product is a drug as defined by the FDA and contained the monograph mandated concentration of the active ingredient, therefore the elimination of the fungal proliferation was expected. We were looking for a skincare regime that brought in additional value in terms of improving the overall skin of the patient, over and above the main clinical objective, which was elimination of the fungal infection. In this respect, the improvements in the skin health observed for all the patients were remarkable based on our visual observations, as well as the simple numerical scoring method we used. We believe that the absence of petrolatum in the product is a major plus, because petrolatum is a known occlusive barrier, and we believe it helps in the proliferation of microorganisms, especially when the underlying environment is moist, dark, warm, and at risk for fungal overgrowth. There is research (6,7) that has implicated petrolatum containing products that promote underlying microbial growth.

The presence of antioxidants is possibly another factor in improving skin health. Hydroxytyrosol, present in olive extract, is known to be a potent natural antioxidant (8), and its presence in the product may have benefits that need further study on larger patient population. In addition, the absence of pruritus was noticeable, and probably contributed to the product's ability to control the spread of the fungus, as scratching tends to spread the pathogens away from the primary affected area. Our initial literature search showed that some of the ingredients present in the product are known to prevent the degranulation of mast cells. A particular sulfur containing ingredient, methylsulfonylmethane, is also known to reduce the conduction of pain stimulus, a factor that may have led to the sense of comfort that these patients felt in using this product.

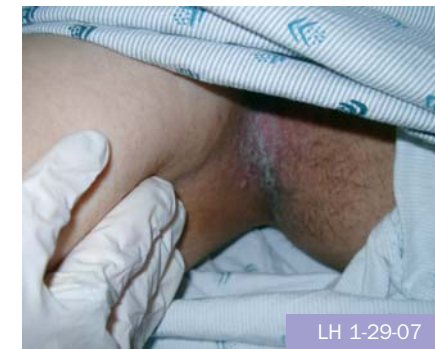We believe that based on the observations of our limited pilot study, further larger scale studies with appropriate controls, randomization, and statistical design may be warranted.

CONCLUSIONS

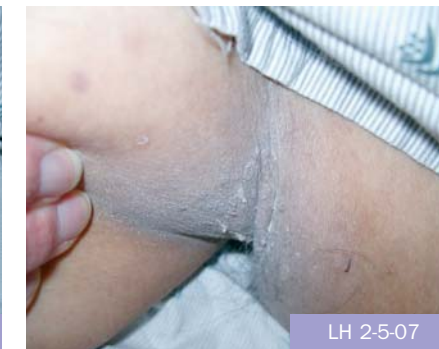It was observed that each of the patients studied had complete resolution of the fungal infection over the course of the study. In addition, quality of life indicators studied, such as erythema, pain, and odor control improved for each patient included in this study. No adverse events, related to the use of the products were observed.

Score Key: 0 Absent 1 Mild 2 Moderate 3 Severe

Criteria Assessed	Before Treatment					Average	After Treatment					Average
	1	2	3	4	5		1	2	3	4	5	
Patient												
Fungal growth	2	3	3	2	2	2.4	0	1	1	1	0	0.6
Pruritus	1	1	3	0	1	1.4	0	0	0	0	0	0
Erythema	2	3	3	2	2	2.4	0	2	0	1	0	0.6
Skin Ulceration	1	3	1	3	0	1.6	0	0	0	1	0	0.2
Pain	2	2	2	2	0	1.5	0	1	0	0	0	0.2
Odor	0	0	2	1	0	0.6	0	0	0	0	0	0

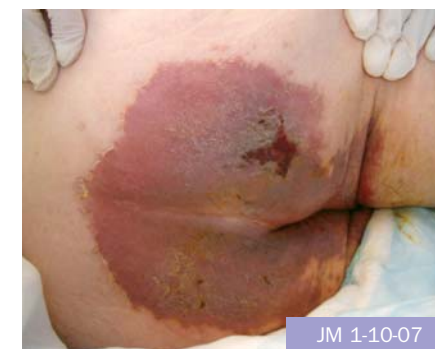

LH 1-29-07

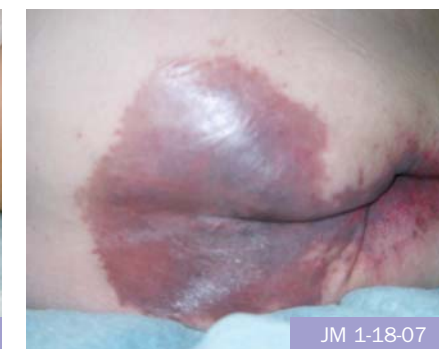

LH 2-5-07

L.H. (Patient 1) is a 75 year old male that was admitted to the hospital with new onset CVA and respiratory failure. He developed cutaneous candida to bilateral axillary areas. Treated for 1 week and candida completely resolved.



JM 1-10-07



JM 1-18-07

J.M. (Patient 2) has a PMH of CVA, DM and ESRD. Currently on G-tube feedings and admitted to the hospital with C-diff. On initial assessment, he had severe dermatitis with ulcerations and cutaneous candida to entire buttock extending into groin. After 1 week of treatment, his ulcerations were completely resolved. Dermatitis still resolving, as patient was still having severe diarrhea.

REFERNECES

- Hahler B. An Overview of Dermatological Conditions Commonly Associated with the Obese Patient. *Ostomy/Wound Management*, Volume 52 (6) June 2006 Pages 34 – 47.
- Hay RJ. The management of superficial candidiasis. *J Amer Acad Dermatol*. 1999;40:S35-S42.
- Trent J, Federman D, Kirsner R. Common viral and fungal infections. *Ostomy Wound Manage*. 2001;47(6):28-34.
- Gallagher S. Morbid obesity: a chronic disease with impact on wounds and related problems. *Ostomy Wound Manage*. 1997;43(5):18-27.
- Gallagher S, Gates J. Obesity, panniculitis, panniculectomy, and wound care: understanding the challenges. *JWOCN*. 2003;30:334-341.
- Ramsey K, Malone S, Fey P et al. Aquaphor as a source of colonization and subsequent bloodstream infections among very low birthweight neonates. *The Society for Healthcare Epidemiology of America*, 1998 Abstracts on Line.
- Campbell J, Zaccaria E. Systemic candidiasis in extremely low birth weight infants: topical petrolatum as a risk factor. In: *Abstracts of the IDSA 36th Annual Meeting-Pediatric Infectious Diseases*. 1998.
- Gordon MH, Paiva-Martins F, Almeida M. Antioxidant activity of hydroxytyrosol acetate compared with that of other olive oil polyphenols. *J Agric Food Chem*, 2001 May 49 (5): 2480-2485.

*Remedy Antifungal Cream from Medline Industries, Inc., Mundelein, IL. Remedy is a registered trademark of Medline Industries, Inc.